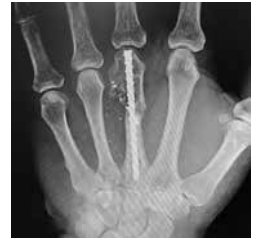

## Case Study

# The Use of Closed Reduction Intramedullary Fixation for Comminuted Neck and Shaft Fractures of the Third Metacarpal

---



## Nathan E. Lesley, MD

The Hand to Shoulder Center of Fort Worth  
Fort Worth, TX

Dr. Lesley received his fellowship in hand/upper extremity and microsurgery from the prestigious Brown University. He also is a fellow of the American Academy of Orthopedic surgeons. Board certified, he specializes in hand, wrist, and elbow.

## Case Presentation

A 54-year-old male with no significant past medical history presented with a self-sustained gunshot wound (GSW) to the non-dominant hand that occurred while cleaning his handgun. On exam, the flexor tendons and digital nerves were intact with slight neuropraxia of the ulnar digital nerve. Patient works as a security guard and is unable to perform his job with activity restrictions. The patient's objective was to return to full activities as soon as possible. When discussing options, the patient requested to minimize recovery time and was reluctant to proceed with any technique which would likely require a second trip to the operating room (OR).

X-rays revealed a highly comminuted fracture of the third metacarpal. Due to concerns about additional shortening, compression screw or K-wire fixation were eliminated as options. Plates and screws were considered, but would need to be applied very distally on the metacarpal head in order to achieve stable fixation. A plate and screw approach would likely result in a need for future procedures, including capsulotomy of the metacarpophalangeal joint and extensor tenolysis.

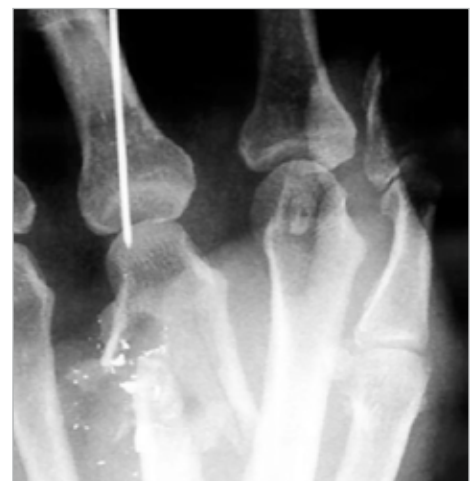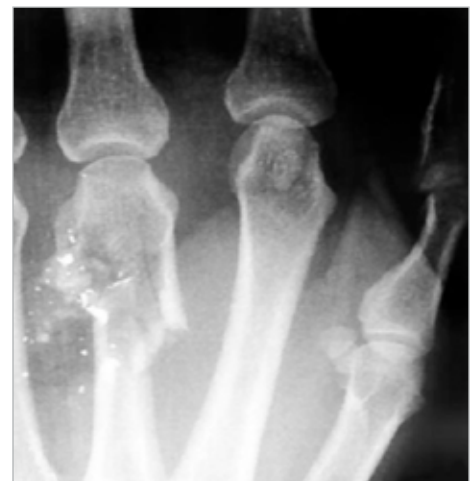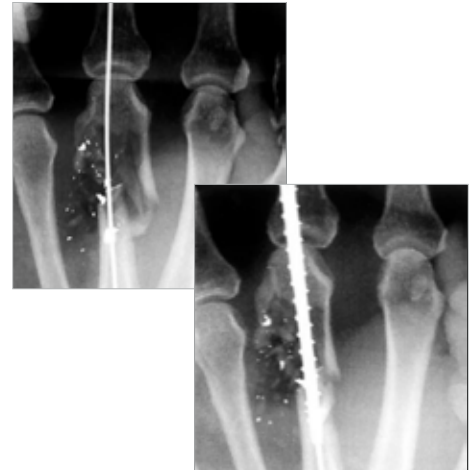
## Preop Plan

All options, including plates and screws, were available. The plan was to proceed with INnate™ nail fixation to achieve a stable construct, allowing early range of motion (ROM) and minimizing the cost and inconvenience of a potential return to the OR. Dr. Lesley felt that due to its non-compressive nature, the INnate nail would effectively restore metacarpal length, which would be determined intraoperatively by comparing the fractured bone to the adjacent metacarpals, as well as utilizing an AP radiograph of the contralateral hand. for the fourth metacarpal through a separate small incision, in an identical fashion. The procedure used 4.5 mm diameter INnate intramedullary nails with a length of 55 mm in both metacarpals. Total surgery time was 25 minutes.

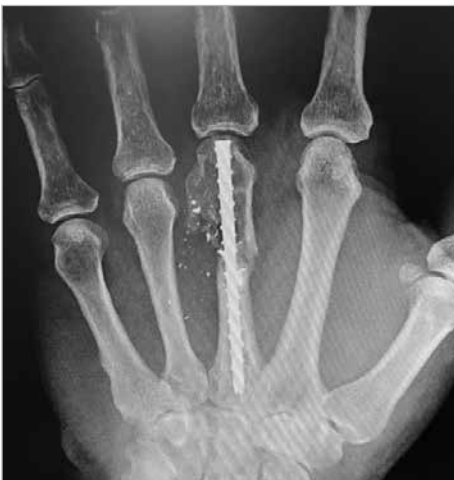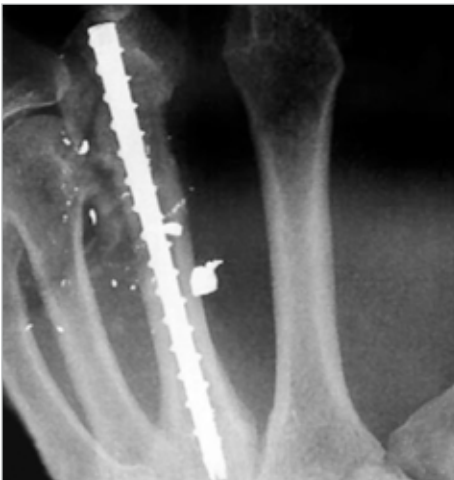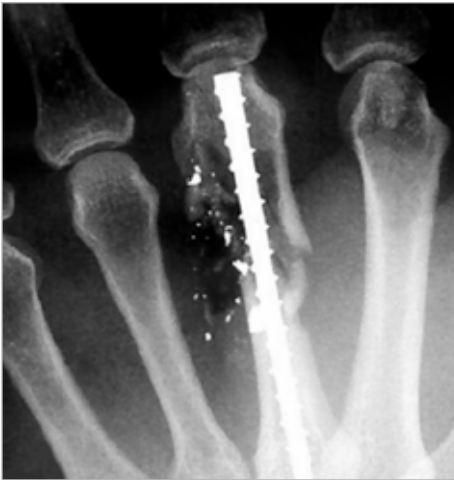## Operative Findings and Approach

The open wounds, volar and dorsal, were explored, irrigated, and debrided. Dr. Lesley confirmed that the flexor and extensor tendons as well as the digital neurovascular structures were grossly intact. A guide wire was placed in the dorsal third of the metacarpal head, and while distracting the metacarpal to the desired height, the length was measured using the INnate depth gauge. He then made a 2 mm incision of the dorsal third of the metacarpal head, drilled using the cannulated drill bit, and advanced a 40 mm threaded nail, while maintaining traction on the digit. The nail achieved proximal purchase at the isthmic level, and was left subchondral, maximizing distal purchase. Full restoration of height was achieved. Total operating time was less than 30 minutes, including debridement.

## Preoperative



## Postoperative



## Follow-up

Due to the extensive comminution, the patient was cautioned against lifting or gripping, but was allowed to begin immediate ROM without the use of a splint. By 14 days post-op, patient had achieved 70% ROM without shortening or extensor lag. Excellent callus formation was confirmed at six weeks, by which time the patient had achieved ROM of 0–85 degree and had already returned to full work duties. Patient declined additional follow-up appointments.

## Discussion

Dr. Lesley's approach allowed the patient to experience excellent outcomes and full functionality that would not have been possible with alternative solutions. The patient's early mobilization prevented the need for physical therapy or time away from work, which would have been a financial burden. Dr. Lesley also reduced his costs by minimizing his time in the OR due to the ease of use with INnate.



**HNW70-84-A**

Effective: 2024/07

© 2024 Acumed® LLC

[www.acumed.net](http://www.acumed.net)

Acumed USA Campus  
5885 NE Cornelius Pass Road  
Hillsboro, OR 97124  
+1.888.627.9957

OsteoMed USA Campus  
3885 Arapaho Road  
Addison, TX 75001  
+1.800.456.7779

Acumed Iberica Campus  
C. Proción, 1  
Edificio Oficor  
28023 Madrid, Spain  
+34.913.51.63.57

These materials contain information about products that may or may not be available in any particular country or may be available under different trademarks in different countries. The products may be approved or cleared by governmental regulatory organizations for sale or use with different indications or restrictions in different countries. Products may not be approved for use in all countries. Nothing contained on these materials should be construed as a promotion or solicitation for any product or for the use of any product in a particular way which is not authorized under the laws and regulations of the country where the reader is located. Specific questions physicians may have about the availability and use of the products described on these materials should be directed to their particular authorized Acumed distributor. Specific questions patients may have about the use of the products described in these materials or the appropriateness for their own conditions should be directed to their own physician.

OsteoMed LLC is a wholly owned subsidiary of Acumed LLC.  
OsteoMed® is a registered trademark of OsteoMed LLC.

ExsoMed™ is a wholly owned subsidiary of Acumed LLC.  
Acumed®, Exsomed™, and INnate™ are registered trademarks of Acumed LLC.