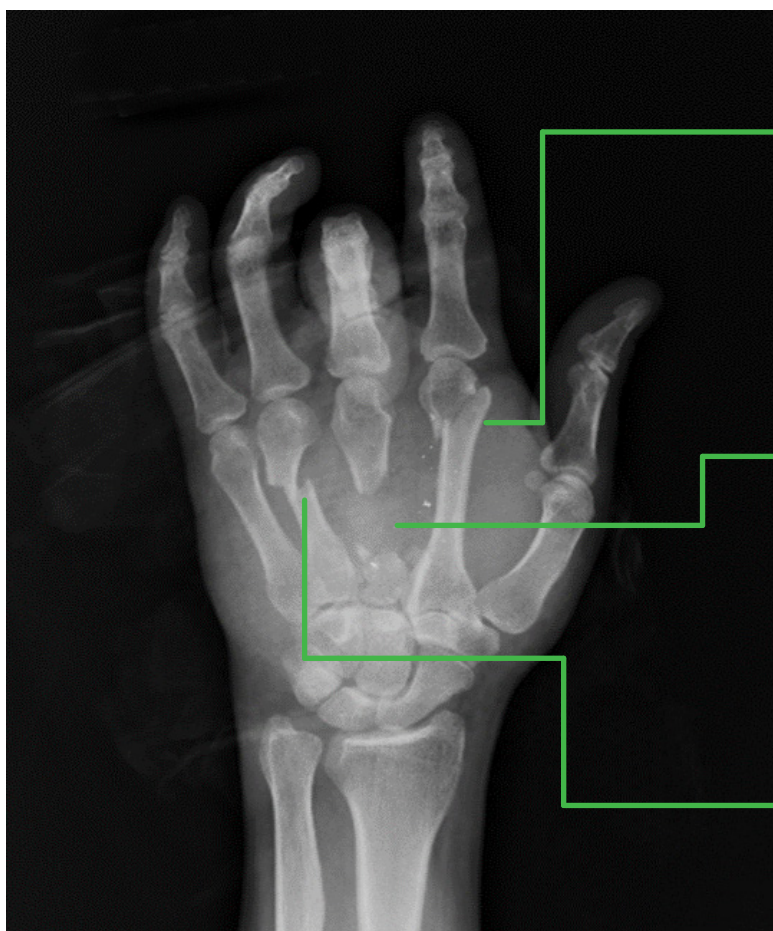


Complex Case Report

Gunshot Wound

Multiple Metacarpal Fracture Fixation & Reconstruction with the ExsoMed INnate™ Intramedullary Threaded Nail

Before Surgical Treatment



Left index finger:

- Oblique displaced metacarpal neck fracture

Left middle finger:

- Metacarpal continuity defect with a comminuted metacarpal base fracture
- **Metacarpal shortening** from continuity defect

Left ring finger:

- Displaced metacarpal shaft fracture

Patient: 47 Year Old Male

Presented with a self-inflicted, accidental gunshot wound to the left hand with multiple open fractures and significant associated soft tissue injuries.

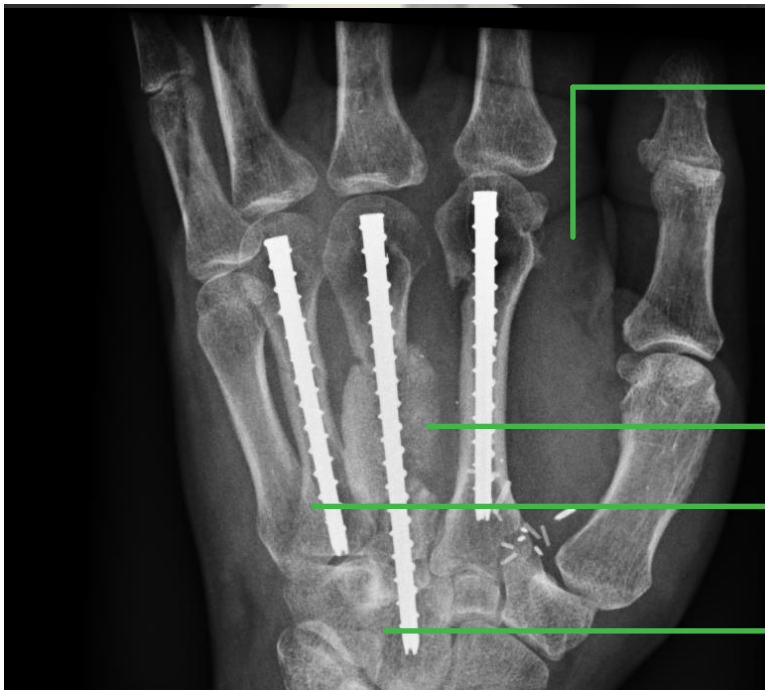Complex Case Report

Gunshot Wound

Multiple Metacarpal Fracture Fixation & Reconstruction with the ExsoMed INnate™ Intramedullary Threaded Nail

After Surgical Treatment

The INnate intramedullary threaded nail was inserted through a cannulated technique for precise reduction of the metacarpal fractures. The threaded nail design is intended to provide rigid fixation and immobilization while avoiding over-compression of fractures. The 4.5mm diameter implant is offered in lengths 35, 40, 45, 50, 55, 65, and 75mm to accommodate fractures of all locations. Sizes 55mm and 75mm were used for this case.



Left index finger:

- Metacarpal fracture stabilized with **55mm** INnate Implant

Left middle finger:

- Metacarpal fracture stabilized with **75mm** INnate Implant and reconstructed with iliac crest autograft - additional bone graft was packed into the volar aspect of the bony defect
- **Metacarpal shortening** was corrected and stabilized with INnate non-compression threaded nail.

Left ring finger

- Metacarpal fracture stabilized with **55mm** INnate Implant

Note: The 75mm INnate Implant was advanced into the capitate for metacarpal stability

Additional surgical repairs completed:

- Decompression of the median nerve and intrinsic muscles
- Flexor tendons repaired
- Reconstruction of the injured ulnar artery
- Reconstruction of the dorsal soft tissue defect with a gracilis free tissue transfer and reconstruction of the dorsal sensory branch of the radial nerve with an interpositional nerve autograft
- Reconstruction of extensor digitorum communis (EDC) tendons of the index and middle fingers and the extensor indicis proprius (EIP) tendon
- Skin grafting of superficial surface on muscle flap